A fundus photograph taken during a cataract surgery. A large, dark, circular pupil is visible in the center, surrounded by the brownish, textured iris. A bright, circular light source, likely the surgical light, is visible in the lower-left quadrant of the pupil. The surrounding retinal tissue is visible in shades of brown and orange.

Beeran Meghpara, MD  
Director of Refractive Surgery  
Co-Chief of Cornea Service  
Wills Eye Hospital

# The Complex Cataract Toolbox

New Orleans Academy of Ophthalmology  
75th Annual Symposium



# Financial Disclosures

- Alcon (C,S)
- Allergan (C)
- BioTissue (C)
- Dompe (C,S)
- Glaukos (C)
- Johnson & Johnson Vision (C,S)
- Kala Pharmaceuticals (C)
- Orasis (C)
- RxSight (C)
- SightSciences (C)
- Sun Pharma (C,S)
- Tarsus Pharmaceuticals (C)
- Thea (C)
- W.L. Gore & Associates (C)
- Zeiss (C)

No off-label discussion







BAERVELDT 250

BAERVELDT 350

MOLTENO

AIMED

CAPSULAR TENSION RING 12

MACKOOL

MORCHER IMPLANT

CAPSULAR TENSION RING

EYEJET CTR TYPE 10C

EYEJET CTR TYPE 13C

MST CAPSULE RETRACTOR

ISTENT INJECT

ISTENT RIGHT

ISTENT LEFT

ISTENT SLIDES

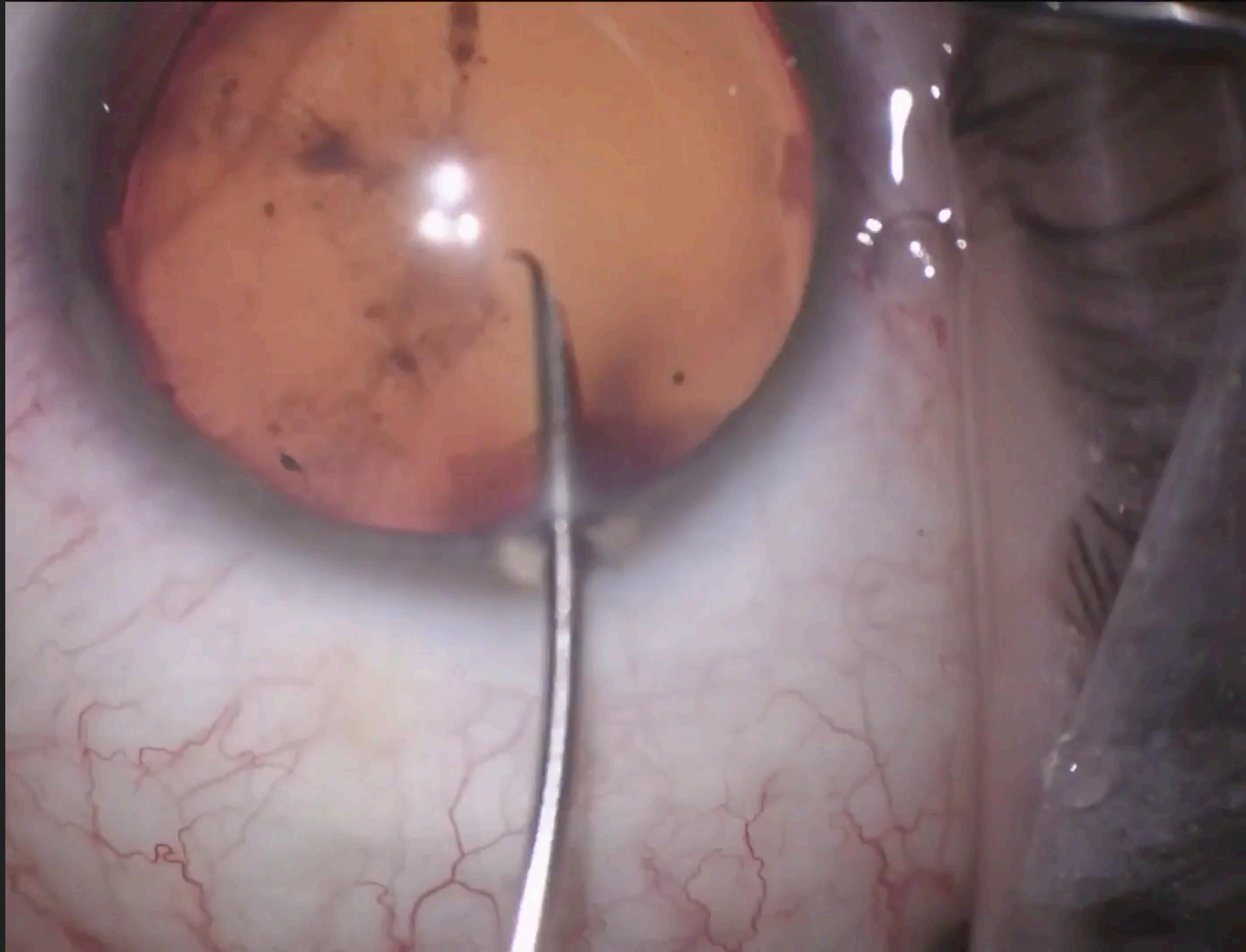
MALYUGIN RING 3.0X

MALYUGIN MANIPULATOR

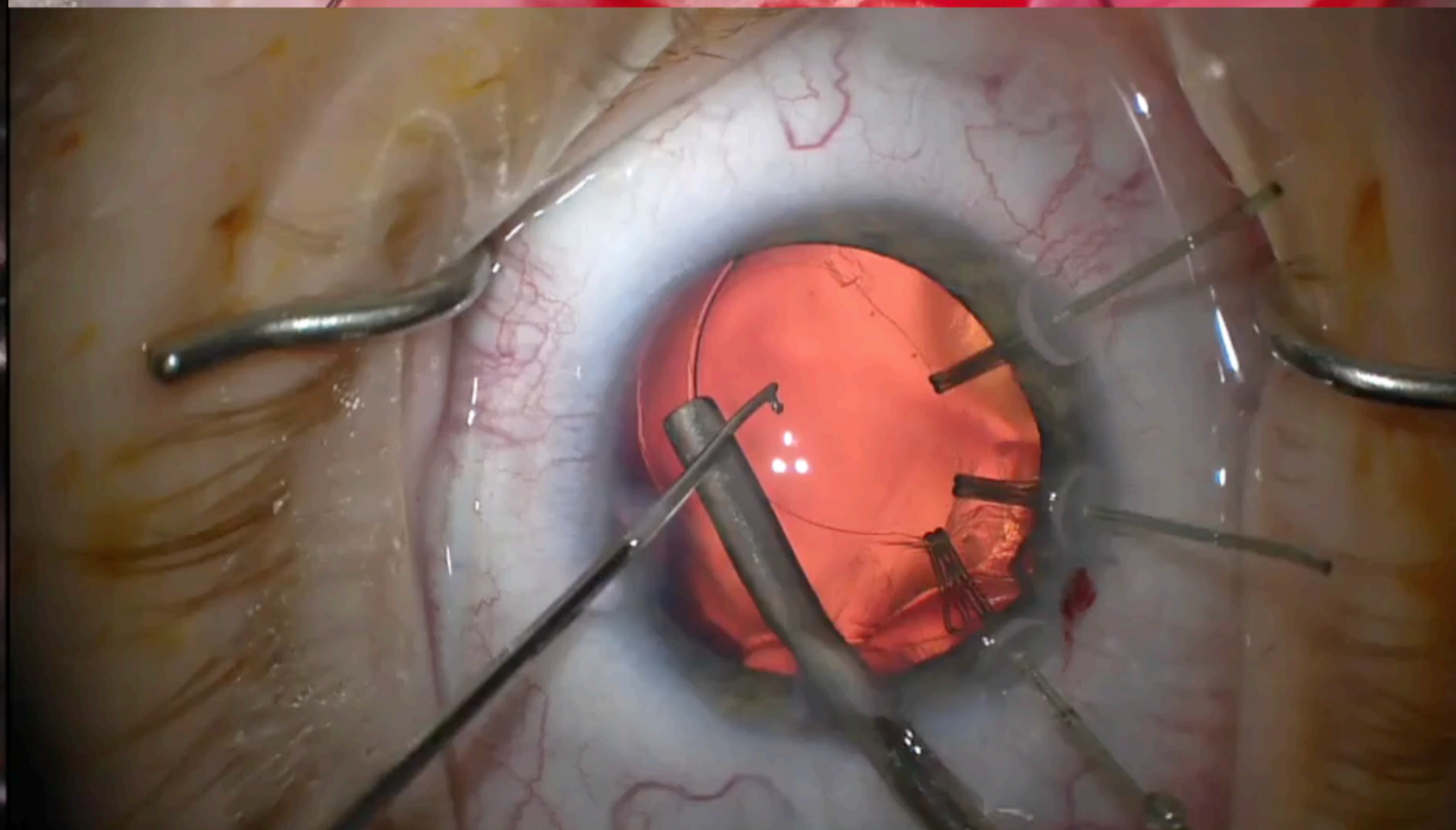
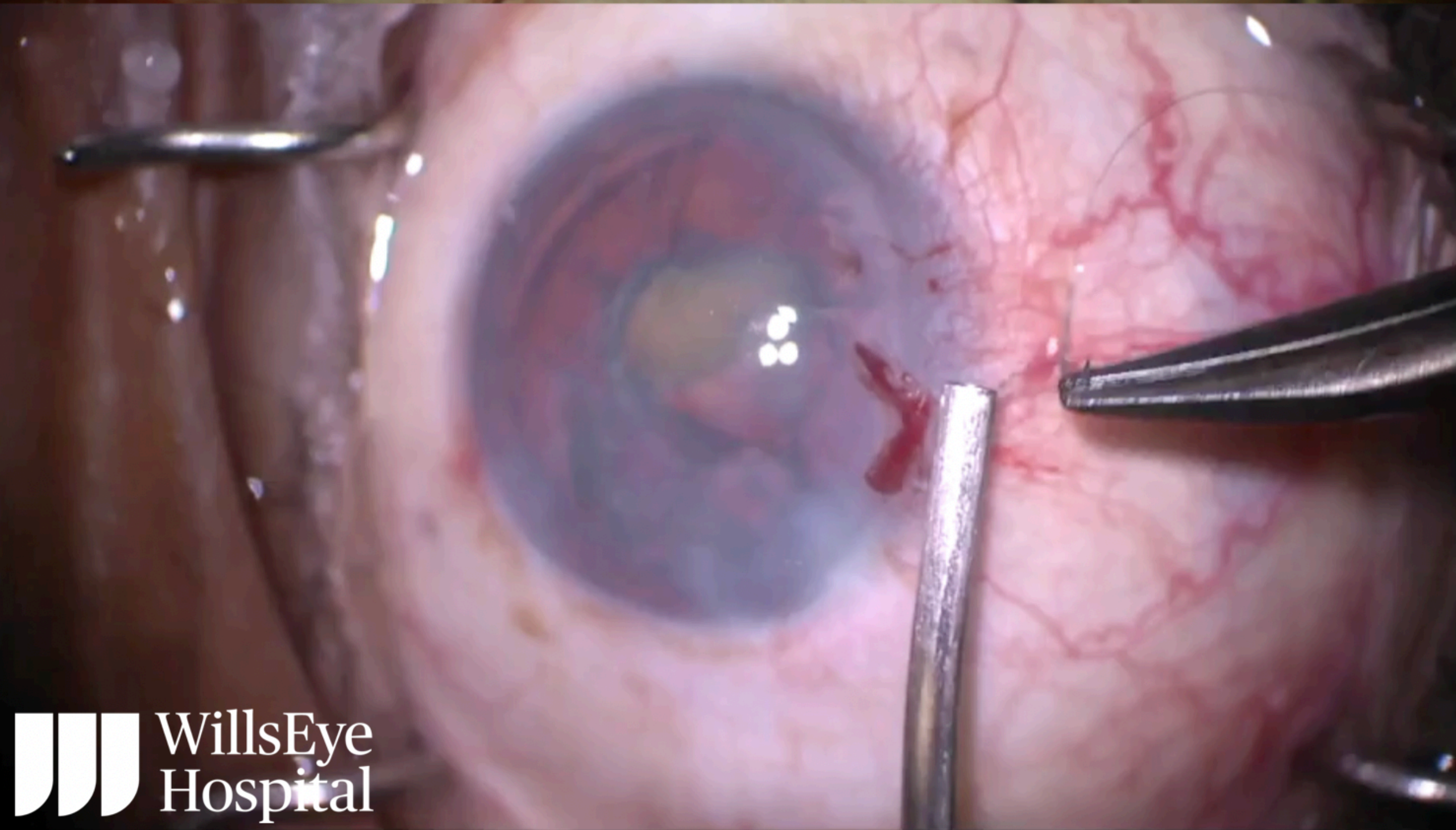
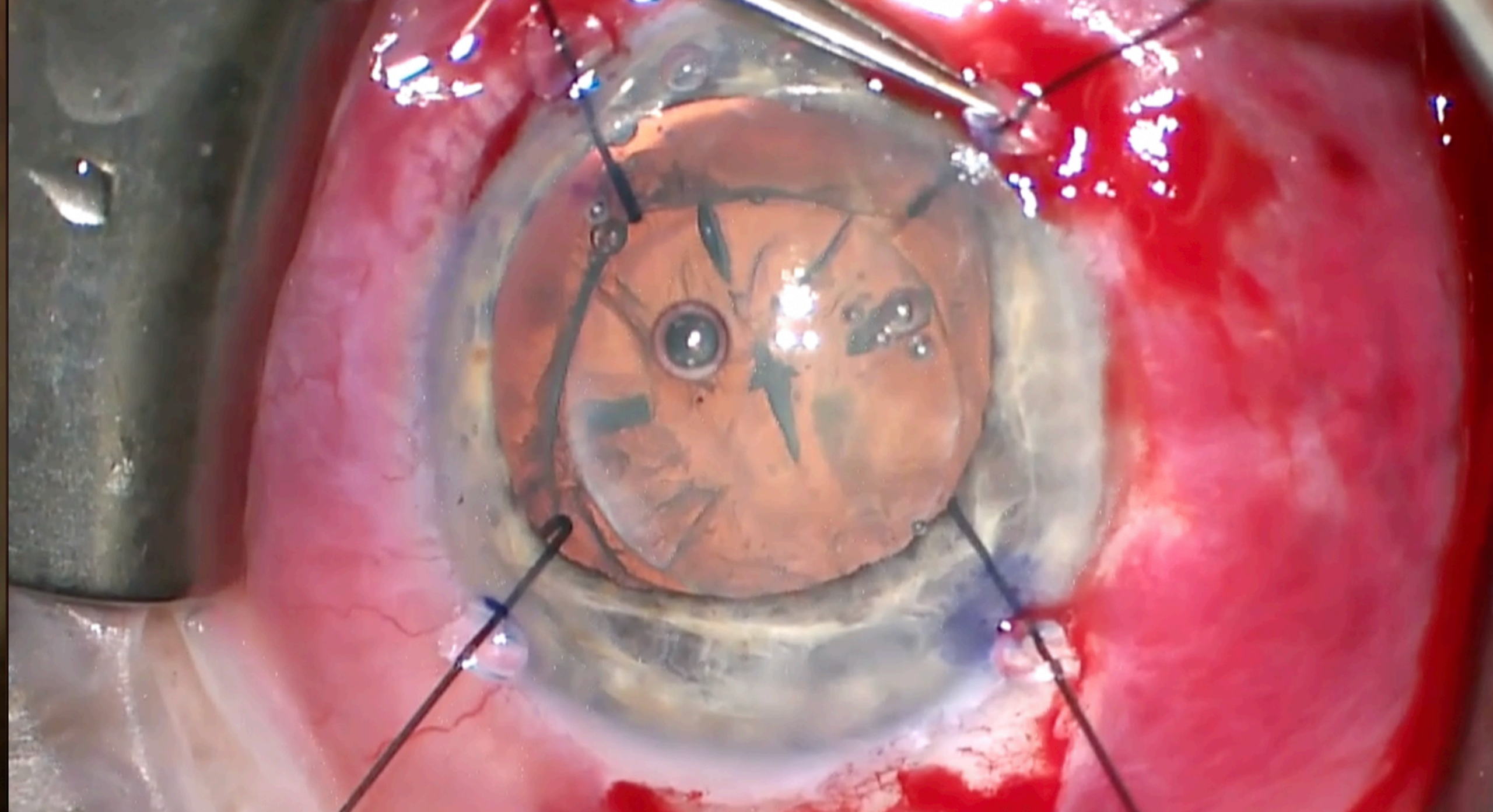
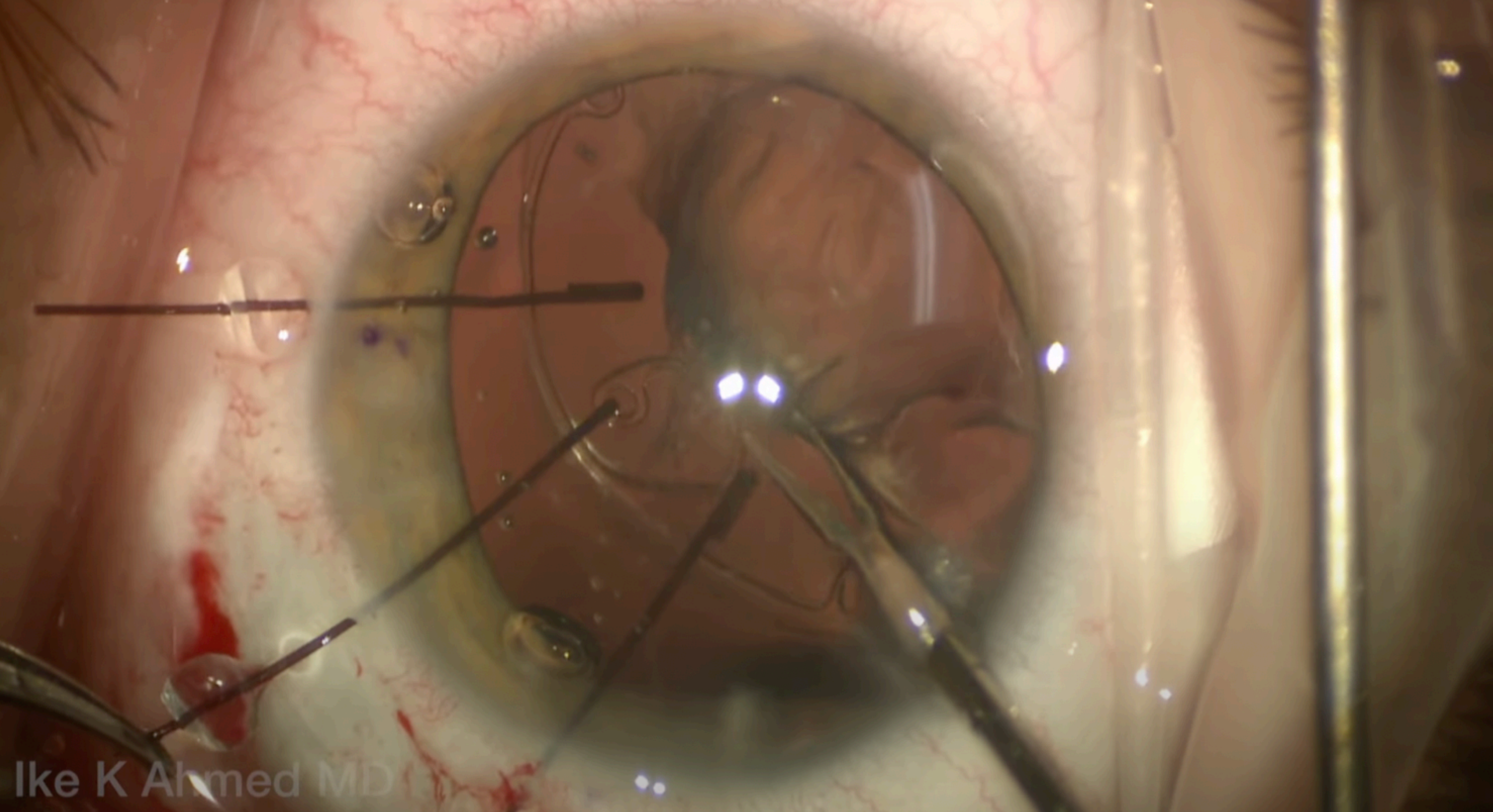
MALYUGIN RING 3.0X




- # Capsulorhexis Capsule Stain
- May be first time
  - Avoid staining under air or BSS
  - Determine where the center is
  - Can inadvertently stain the vitreous
  - A second instrument may be helpful to keep the bag stable
  - Capsular stability markers can be placed to move the lens to complete the capsulorhexis








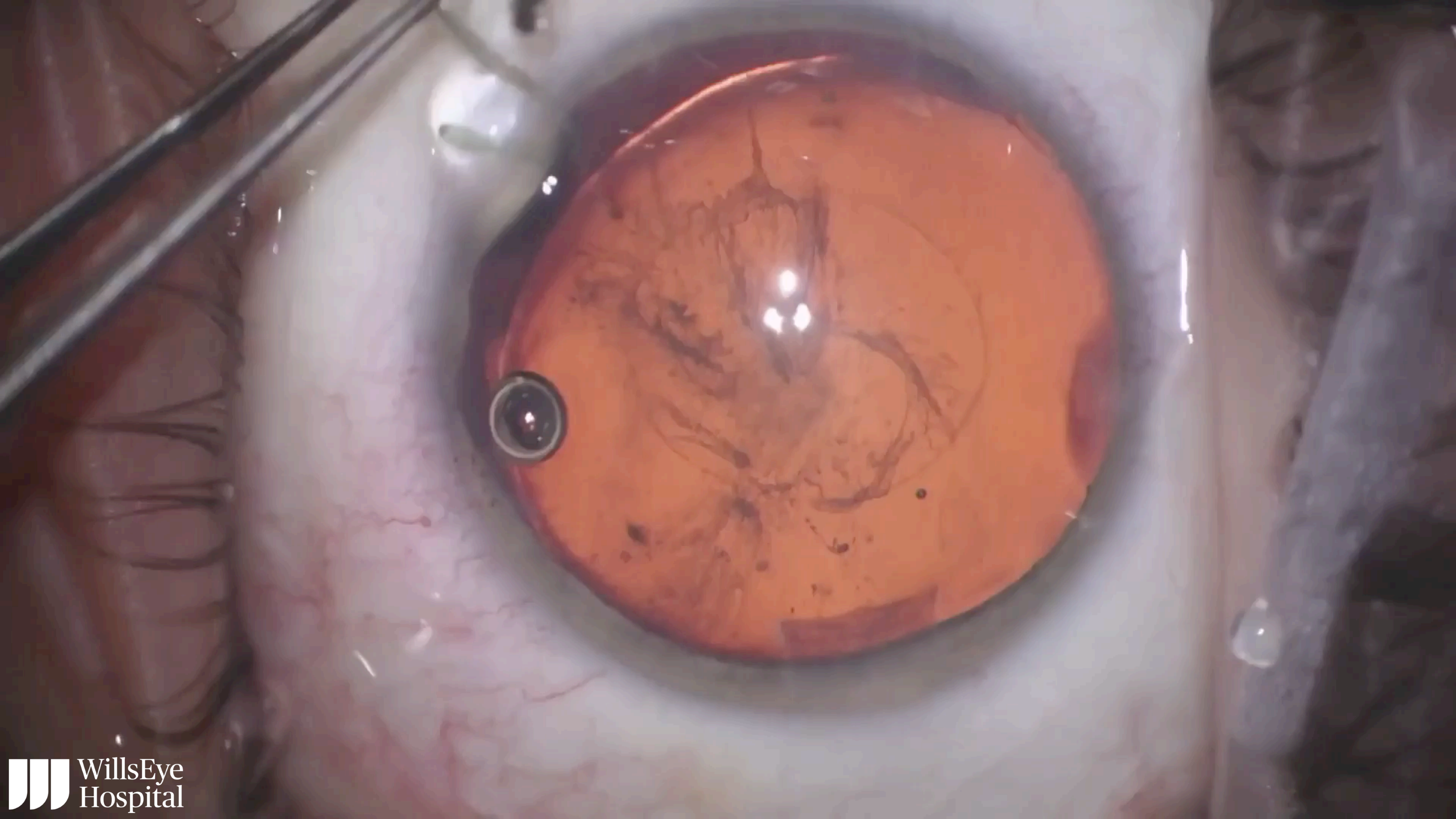




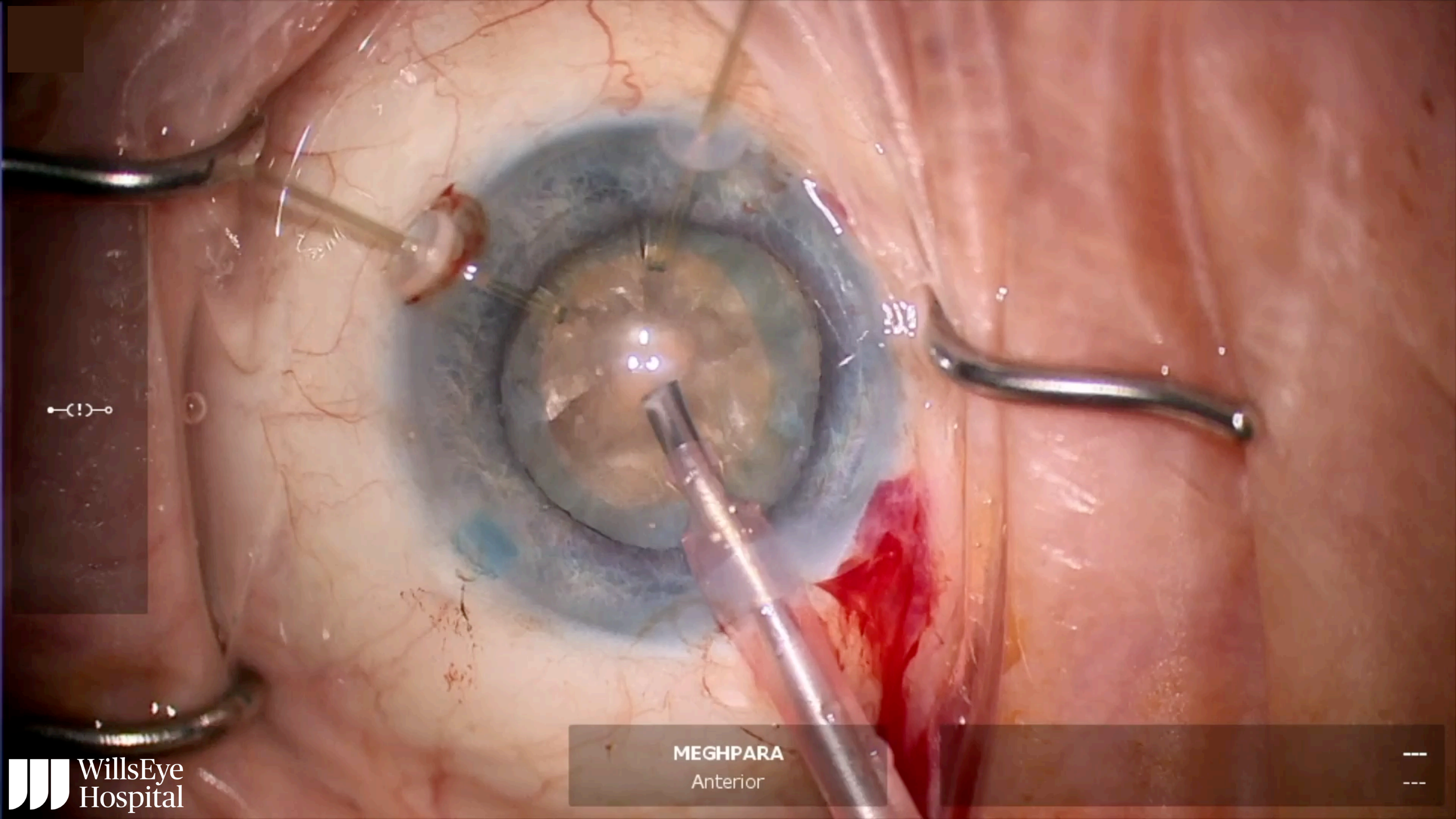








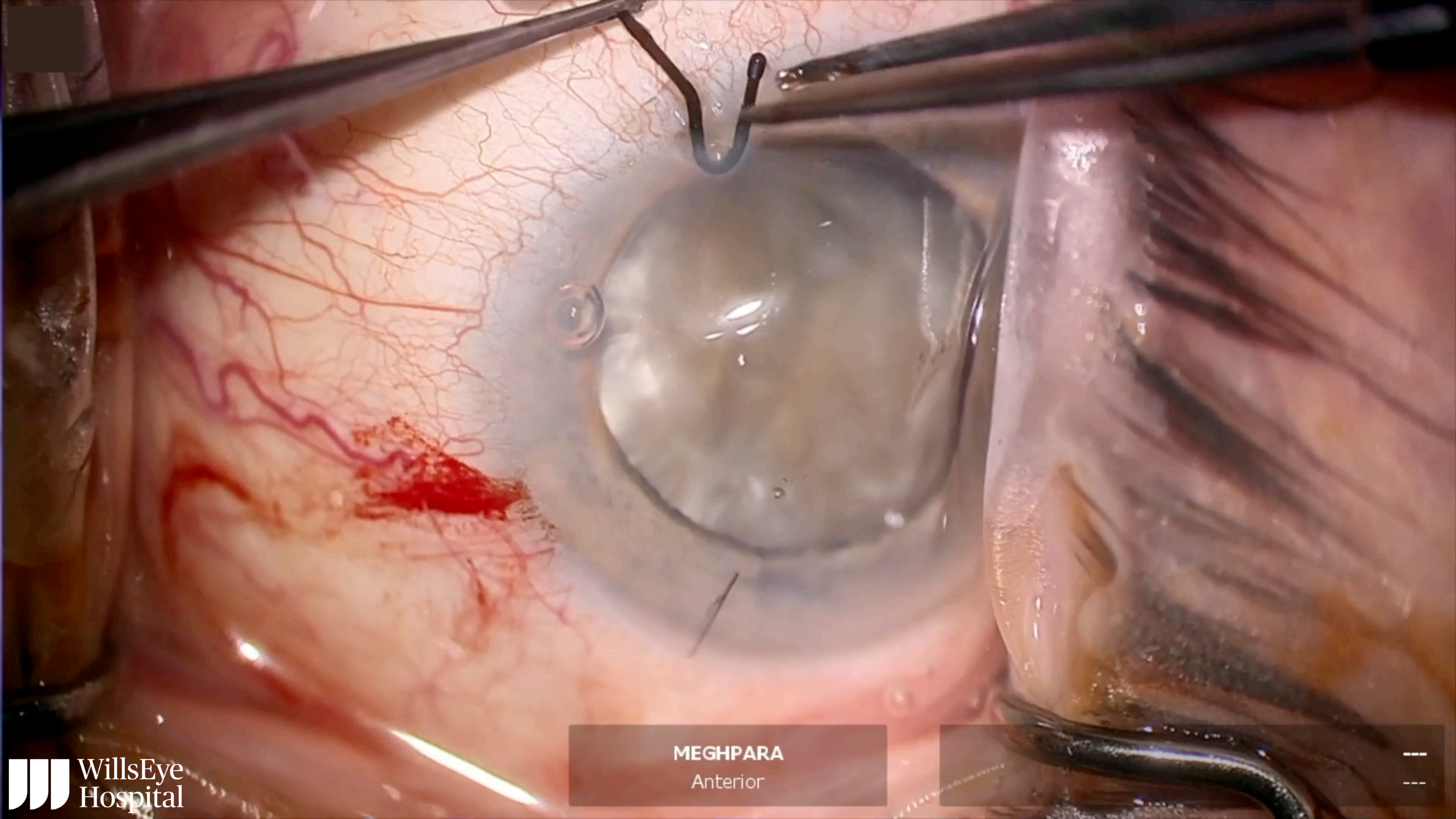




—(!)—

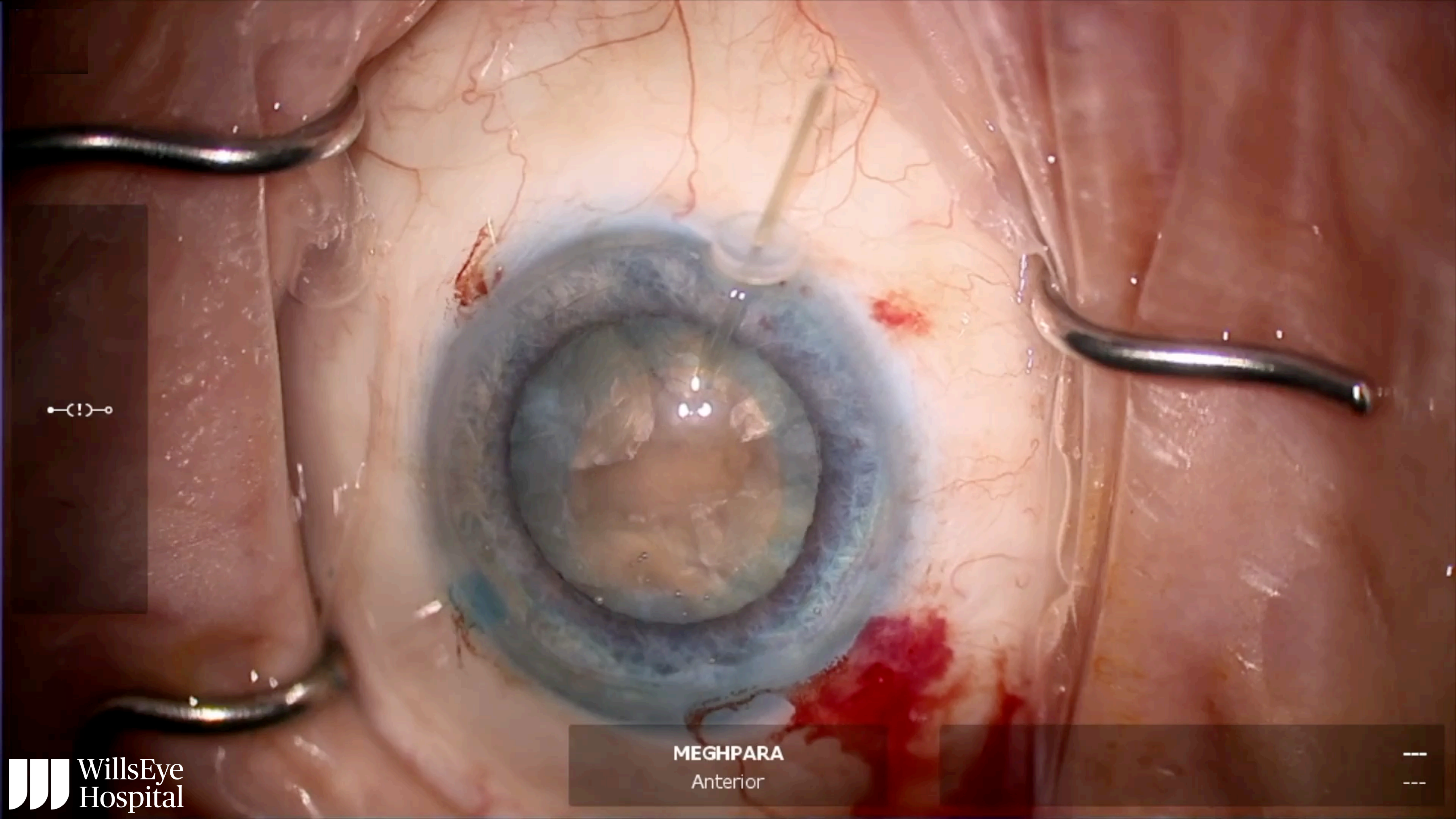
MEGHPARA  
Anterior





MEGHPARA  
Anterior





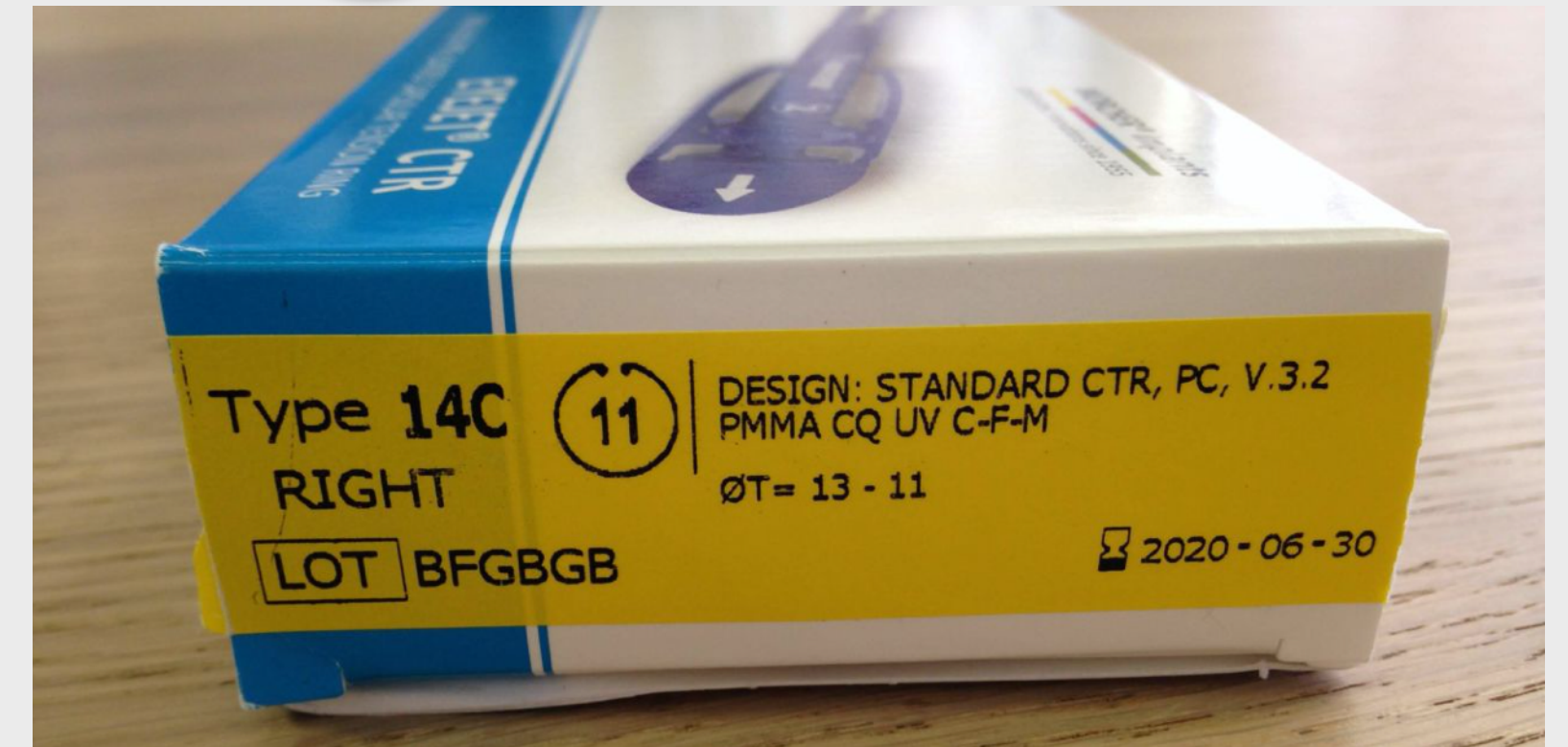•(!)•

MEGHPARA  
Anterior



# Capsule Tension Ring Size

- Based on axial length
- Morcher ring
  - Size 14 (12.3 compresses to 10.0)
  - Size 14c (13 compresses to 11)
  - Size 14a (14.5 compresses to 12)



AL <24

AL 24 - 28

AL >28

Correctly sized ring has ends that slightly overlap each other



# Capsule Tension Segment

Partial PMMA ring (120 degrees) with raised single eyelet that is designed to sit anterior to the anterior capsule

## Versatile

- Temporary support during phaco
- Scleral fixate for permanent support
- Can use in compromised capsule







Eyelet Raised  
Above Segment





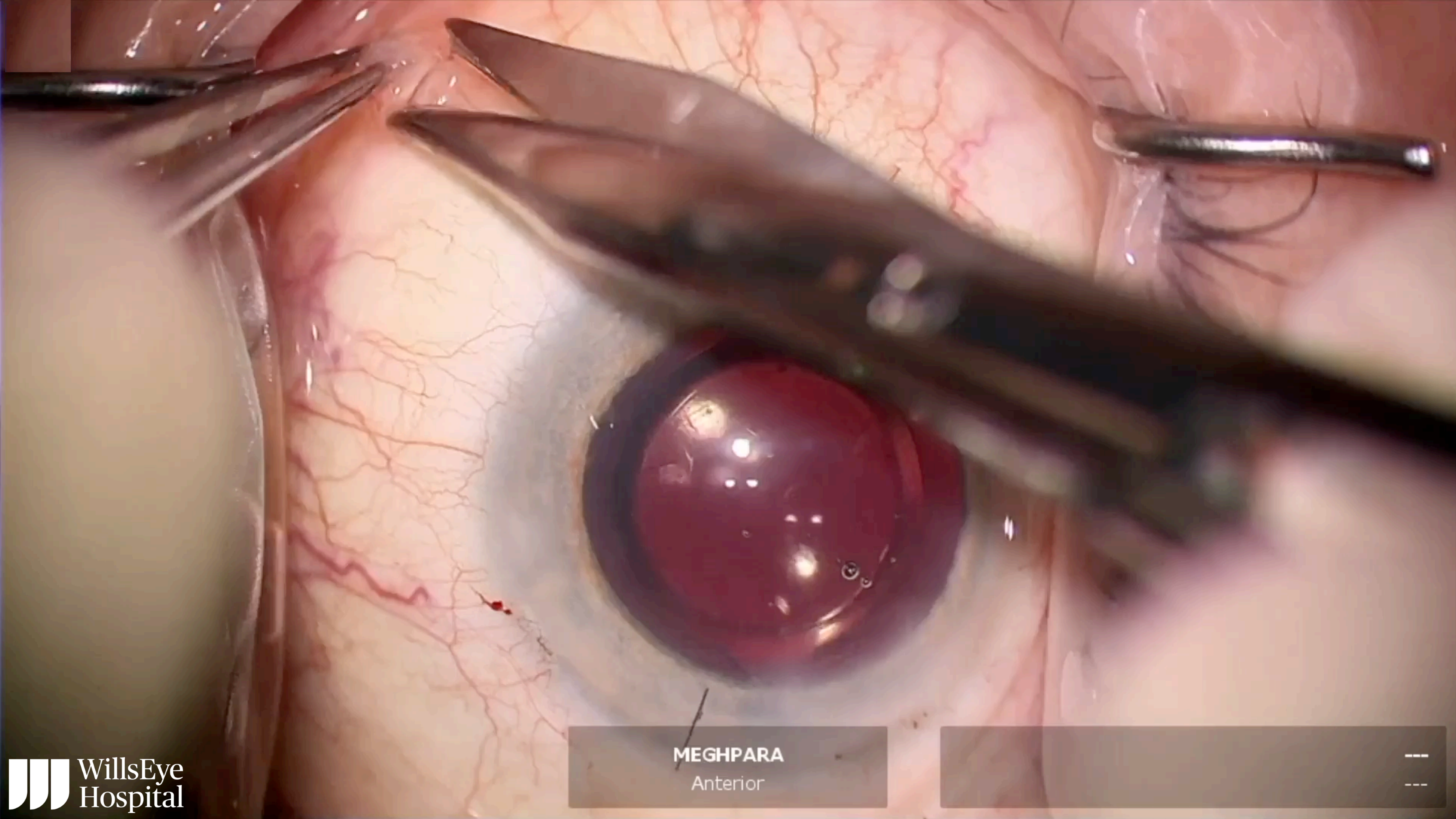
# Capsule Tension Segment

## *When To Use It:*

- Typically greater than four clock hours
- Marked general zonular weakness with phacodonesis
- Low threshold in progressive zonulopathy (pseudoexfoliation)
- One or two can be placed

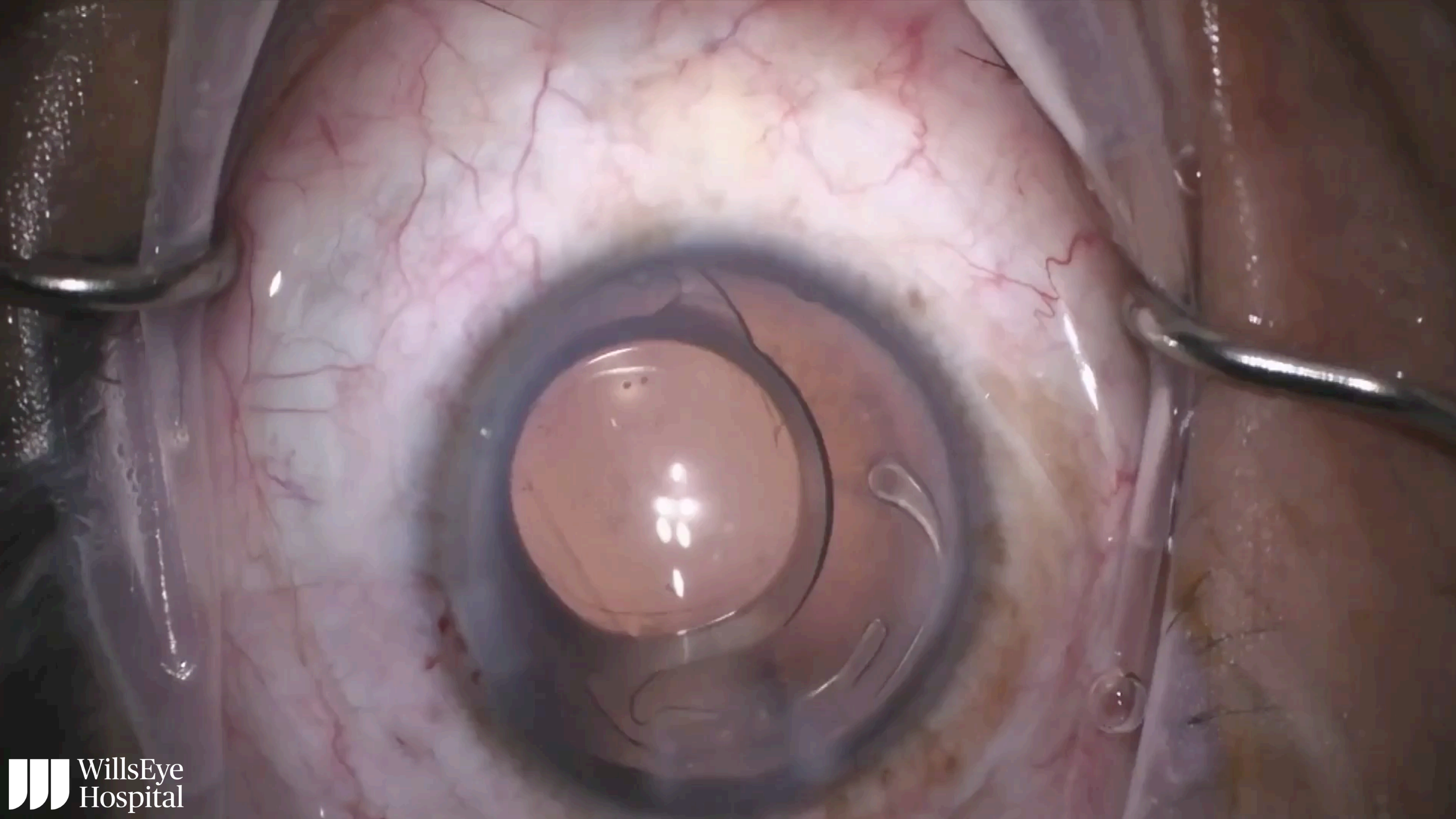






MEGHPARA  
Anterior

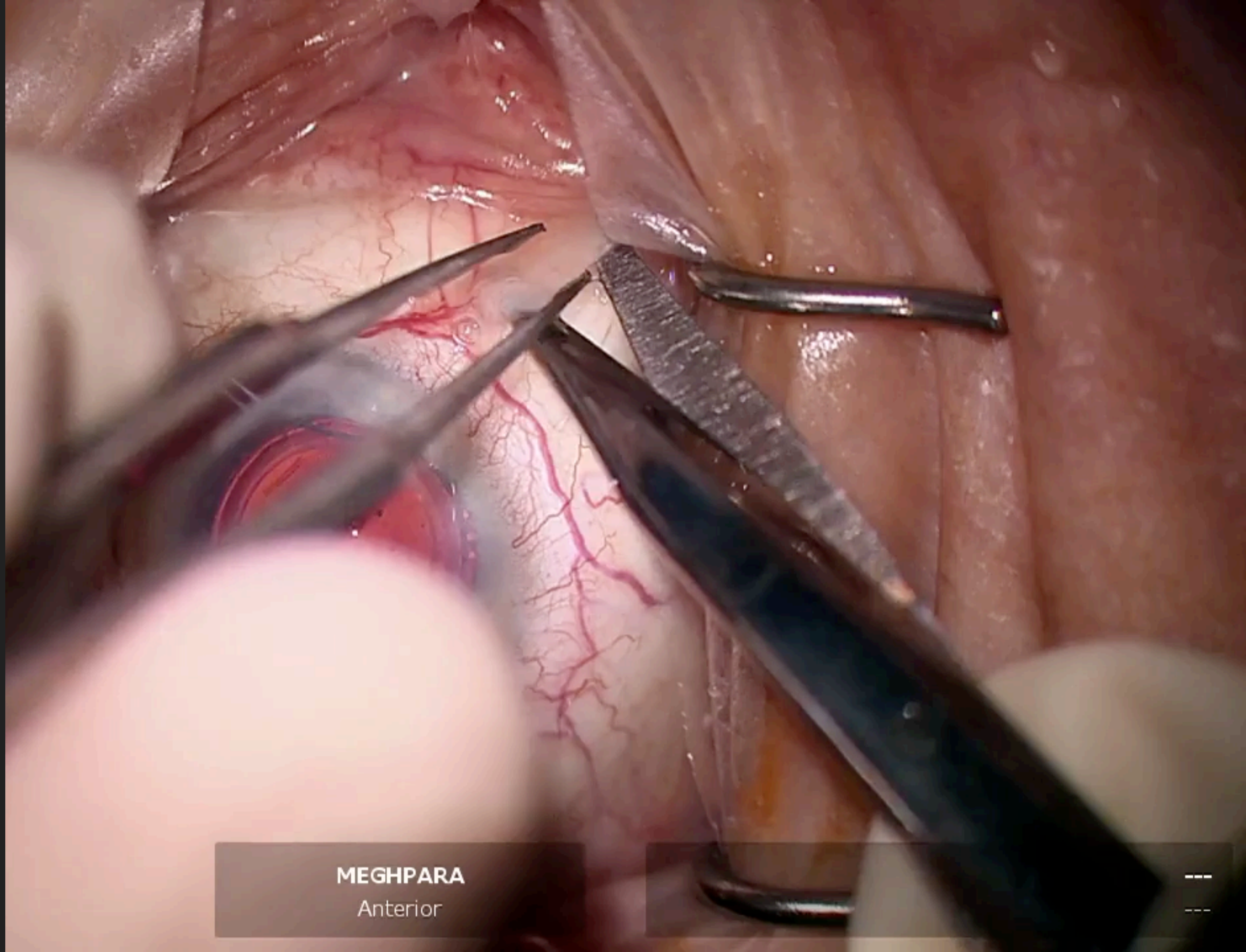






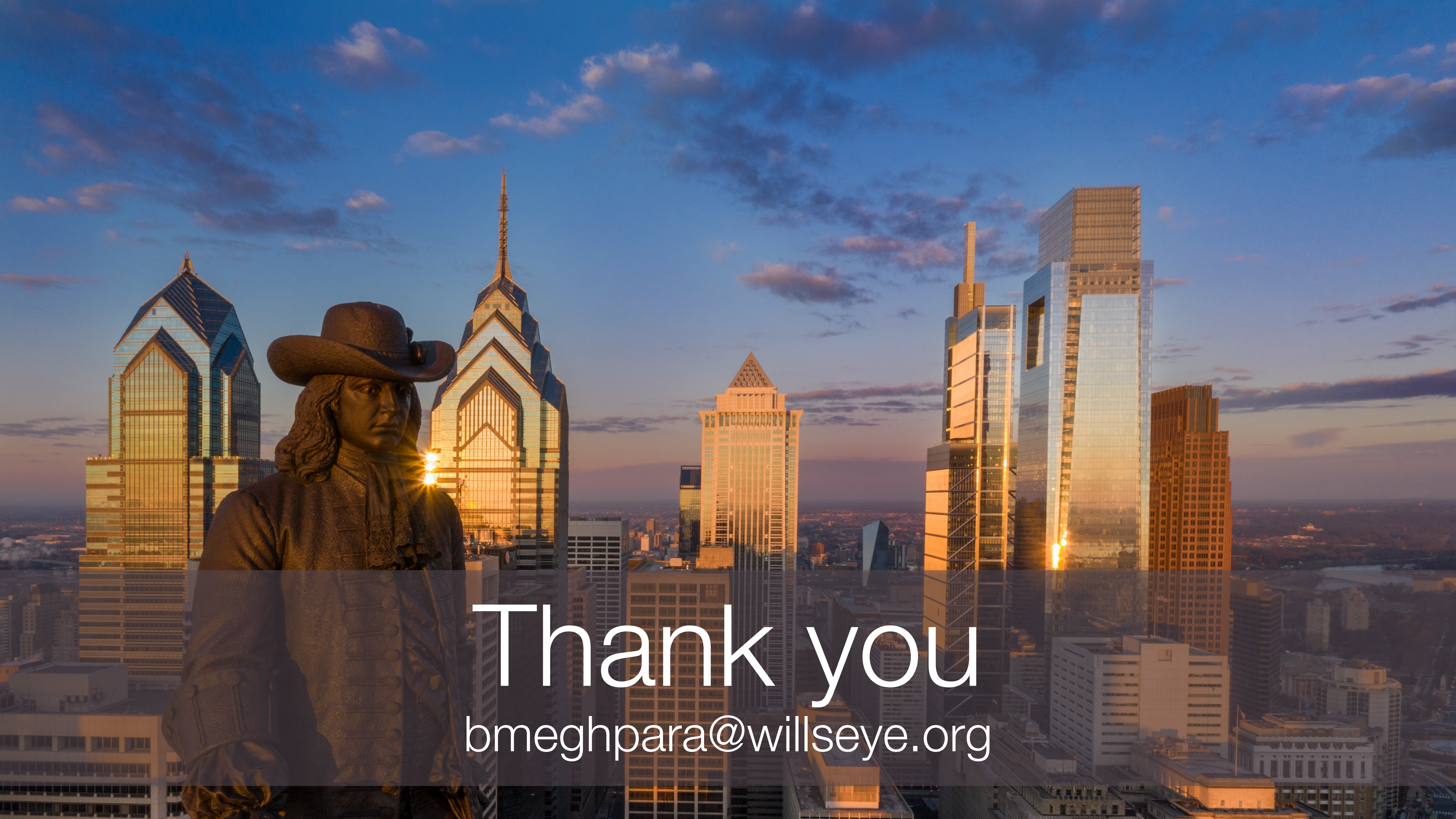# Vitrectomy

- Not uncommon for vitreous to prolapse anteriorly
- Be comfortable with cut-down block and bimanual anterior vitrectomy
- Use triamcinolone to help visualize vitreous
- In uncomfortable with vitrectomy, operate with a vitreoretinal surgeon



MEGHPARA  
Anterior





Thank you  
[bmeghpara@willseye.org](mailto:bmeghpara@willseye.org)